The Madras Clinical Journal

Vol. XXVIII FEBRUARY 1962 No. 8

CONTENTS

		Page
1.	Common Orthopaedic Conditions ... ... — K. A. Ramalingam	227
2.	Some Vascular Disorders and their Ocular Manifestations ... — K. S. Subramaniam	237
3.	Acute Abdominal Emergencies in Infants and Children ... — C. N. Santhanam	243
4.	Abstracts and Excerpts	253
5.	Association Notes	256
6.	Review	236
7.	Obituary	255
8.	Indian Council of Medical Research	258
9.	10th Madras State Ophthalmic Conference	235
10.	Editorial Announcement ... ... Cover	3

AMITROL TABLETS

For various Cardiac troubles

PREDAPHYLLINE TABLETS

(WITHOUT EPHEDRINE)

For Cardiac and Bronchial Asthma

TRANQUILON TABLETS

For anxiety tension states, insomnia, muscle spasms, premenstrual tension, psychosomatic states etc.

For detailed particulars, please write to:

USAN LABORATORIES PRIVATE LTD.

Amin Villa, 13, Dattatray Road, Santacruz West, Bombay-54.

PERIHEMIN*

Hematinic Lederle

*Trademark

Nine out of 10 of all treatable anemias respond to PERIHEMIN. Its potent formula includes every known hemopoietic agent, including AUTRINIC* Intrinsic Factor Concentrate. With this single product, you provide complete anemia therapy in a form convenient for the patient.

Dosage: one capsule, t.i.d.

Each capsule contains:

Vitamin B12 with Intrinsic Factor Concentrate 1/3 U.S.P. Unit (Oral †)

Vitamin B12*	5 mcgm.
Ferrous Sulfate (Exsiccated)	192 mg.
Folic Acid	0.85 mg.
Ascorbic Acid (C)	50 mg.
Insoluble Liver Fraction	50 mg.

Supplied in bottles of 25

dry filled sealed capsules (a Lederle exclusive!) for more rapid and complete absorption!

† Established prior to addition of other ingredients

* As present in concentrated extractives from streptomyces fermentation and in addition to that contained in Vitamin B12 with intrinsic factor concentrate.

Lederle

LEDERLE LABORATORIES (INDIA) PRIVATE LIMITED

P. O. B. 1994 BOMBAY 1

FOR CIRCULATION AMONGST MEMBERS ONLY

The Madras Clinical Journal

JOURNAL OF THE MADRAS STATE BRANCH OF THE INDIAN MEDICAL ASSOCIATION

(WITH WHICH IS INCORPORATED THE "MISCELLANY")

Vol. XXVIII February 1962 No. 8

COMMON ORTHOPAEDIC CONDITIONS *

K. A. RAMALINGAM, F. R. C. S , (E.),
Muthu Clinic, Elukadal Street, Madurai.

It is a great privilege conferred on me to address you at this annual meeting of your branch. I feel proud, indeed, to be here for more than one reason — it is here I was born and bred. I must thank the enthusiastic secretary for his kind invitation. My choice of topic this evening may leave some wondering what I am going to pick up for discussion. I must confess that common is a term which varies from place to place — I shall endeavour to talk to you the common things which we ought to know for a general practice. I shall also combine brevity with clarity without sacrifice of facts and leave out pedantic dissertations on such topics as electrolyte balance study and theories of shock. In my deliberations, I will illustrate certain points with case notes taken from my file and those from Government Hospitals and if I point some mistakes in any one of them, it is definitely not to show the mistakes of others, but to bring to you the correct ideas vividly. At this juncture I need not tell you of some of the eminent surgeons writing on their mistakes in diagnosis and treatment, like Bowden — to teach us to remember certain points in mind always during such similar procedures. Pardon me if the subject is too elementary, but I am confident I will refresh elementary principles of treatment.

Congenital club foot (Talipes Equino-Varus) deformity: This is the commonest deformity we see in a new-born infant and it requires treatment even on the first day of the life of the infant. We should take care to differentiate the normal physiological inversion attitude of the feet which the new-born adopts for a few weeks; it is correctible by manipulation; it requires no treatment. In club-foot there is adduction and inversion of the forepart of the foot; the arch is higher than normal with prominence on the lateral surface of the foot in

* Lecture delivered during the Annual Meeting of Ramnad Branch of I. M. A. on 20th August 1961 at Virudhunagar.

the region of the cuboid and the base of the 4th / 5th metatarsal. Males suffer more than females — 55% and 45% respectively and it is bilateral in 51%.

The treatment is started on the first day of the birth of the infant. Hold the fore-part of the foot in one hand and the heel in the other and bring the forepart in abduction and make pressure inwardly on the prominence on the lateral border of the foot; holding the foot all the while very firmly for half a minute,- release it and repeat for another half minute continuing until you spend five minutes on the foot morning and evening. If the infant is brought to you weeks later, the manipulation has to be done under an anaesthetic. The deformity is over - corrected in eversion and abduction and maintained by adhesive plaster strapping. If there is no improvement within a month's time, then we must employ Dennis Brown's splint. I myself will not think of applying a plaster of paris cast to correct it, because it prevents the infant kicking about with its agile foot and hence wasting of the muscles of the limb is inevitable. Kite's wedging the plaster-technique is an ingenious procedure for a resistant case in a grown up child which aids correction in stages one deformity after another. Because of failure to do this elementary things to a club foot infant even on the day of his birth, we allow him to grow with persistant deformity that throws him out of society with complexes or necessitate a triple arthrodesis.

Meningocele: Often times my obstetric friends and some general practitioners see new born infants with a swelling in the low back and provisionally we make a diagnosis of meningocele, but the real problem is advising the parents of the infant regarding the treatment and satisfy ourselves regarding the differential diagnosis. A prerequisite in all these cases is the correct assesment regarding any associated deformities like club-foot – hydrocephalus – also bladder and rectal functions. A pure and simple meningocele is amenable to surgical treatment and can be operated at the earliest opportunity when the child is free from any infectious disease, whereas in a case of myelo – meningocele, when the contents of the sac is nerve roots and when there is associated hydrocephalus, operation is deferred and the mortality rate is 70% in these cases. Those cases who grow up to adolesence with this defect of myelo - meningocele present problems of dribbling of urine and incontinence of rectum and it is the realm of the specialist to rehabilitate and educate and provide proper appliances for the maintenance of bladder function. No surgery is attempted either for correction of limb deformities or for the bladder except probably bladder neck resection in selected cases. The other problem in this case is differential diagnosis from sacro-coccygeal tumour which is also present in the infant. A meningocele is associated with spina-bifida and usually club foot or claw foot deformities due to neurological deficit, whereas a sacro-coccygeal tumour does not have either a spinal defect or a neurological deficit. A word of caution is given regarding unnecessary delay in operating on cases of meningocele; they are prone to rupture and cause infection and meningitis; it is equally true that a few come to us with ulceration of the overlying skin and slow leakage of the C. S. F. We are often in a dilemma whether to operate at once or not and the chances are

even and we must operate under anti-biotic cover and chances of the infant developing meningitis and dying is even.

Scurvy: Recently in a fortnight's time I came across two cases of scurvy—one was treated by a general surgeon as osteo-myelitis of the lower end of the femur in a child 10 months old and another as paralysis of left lower extremity due to poliomyelitis. Both proved radiologically and therapeutically as infantile scurvy. I cite these two cases to impress on you the different manifestations of scurvy in infants and also to show that you must always bear in mind scurvy for a differential diagnosis for a tender swelling of the joints. Sometimes even with x-ray pictures a surgeon is led astray. Unlike in the adult where scurvy manifests by bleeding gums, the infant between 6 to 24 months, bottle-fed, is brought to us for fever and joint swelling with exquisite tenderness and unless we keep in mind scurvy also, we may diagnose it as osteomyelitis or pseudo-paralysis which are also commonly seen in that age group. The x-ray shows loss of density; the cortex is thinned and forms a conspicuous fine line limiting a ground area formed by cancellous bone. At the extremity of the metaphysis between the clear zone and the epiphysis is a dense line "White line of Fraenkel" with the lateral spur of Pelkan. In exceptional cases the displacement of an epiphysis may be complete due to subperiosteal haemorrhage which is a very important clinical feature causing swelling and pain and we may see calcification of the haematoma after 10 days. The anterior ends of the ribs are expanded to a marked degree, but do not show "cupping". The therapeutic test is particularly diagnostic in scurvy; we give vit. C. 500 to 1,000 mgm. intravenously and the result is remarkable within 12 hours. Patient becomes quite afebrile and the swelling subsides with no pain or tenderness.

Rickets: This is another common metabolic disorder seen in malnourished children who present with a pot belly, bossing of the skull and with bony deformities. They get enough of sunlight, but vit. D. 10-20,000 INU improves the condition and skeletal deformities can be corrected by orthopaedic procedures.

Osteomalacia or Adult Rickets: This is often missed by a general practitioner. This usually occurs in women who suckle their babies for a longer period. They report with the complaint of pain in the chest and exhaustion. Even radiographs of the chest are taken and sent with the report "lung fields clear". But when radiographs are taken for ribs, they show areas of rarefaction with pathological fracture known as Looser zone. The cases respond well with administration of vit. D and calcium and the mothers are advised to wean the babies.

Paralytic Affections: I do not wish to deal at length on the different aspects of cerebral palsy or paralysis after poliomyelitis. It is a very fascinating subject and I hope to touch on certain principles of diagnosis and treatment which every one ought to be familar with, either to advise the patients properly or treat the disease in the early stages satisfactorily to avoid humiliating deformities later. I wish to point out the magnitude of the problem by telling you that 75% of the crippled we see on the roads would have led a much better life if only we had attended on them in the early stages. The fault lies on both

sides, because the patients are ignorant of the facilities available and remain content thinking it is the curse of God. "Cheated by feature, by dissembling nature, deformed, unfinished, sent before my time into this breathing world, scarce half made-up, and so lamely and unfashionable, that dogs bark at me, as I halt by them". The medical men were not very familiar with reconstrutive surgery or the physiotherapy and rehabilitation works. I shall deal here with a few minor deformities correctible in the office. I see more and more general practitioners prescribe splints and splints alone for all types of paralysis; I am pained to see that the problem instead of being analysed in an arthimatic fashion, is relegated to a splint maker. I believe proper splint or prosthesis making is a far advanced science. Every case requires an elaborate discussion with colleagues and assistants to assess the type and the need. Some may just need a mere tendon transfer or lengthening or an arthrodesis to make him go about as you and I. Why then subject him or her to a life of humiliation with a splint ? Of course, no one will disagree on the use of a well made splint; it is a real asset to a cripple, but it is not the end-all.

Miss. J. A., a three years old child had an attack of fever and after she became afebrile the parents noticed that the child was not able to walk; so the general practitioner referred the case to a senior practitioner and he diagnosed foot-drop and prescribed a foot-drop caliper. I saw the child was still not able to walk with the caliper on, all in a matter of 10 days after fever with this treatment, the diagnosis is still poliomyelitis. The point I want to emphasise is that one should never prescribe a walking caliper alone within 6 months. The proper line of treatment for the paralytic type of poliomyelitis will be absolute bed rest in the first two weeks, not even combing of hair or eating with hands; sedatives and analgesics are prescribed to alleviate muscle pain and restlessness. Bed rest is continued on with proper support of the limbs either in plaster or on splints to avoid contractures and deformity. No massage is permitted while pain is present. After the second week, when muscular pain disappears, passive movements are started combined with graded exercises short of causing fatigue. Then; by the end of a month, the child is made ambulant by encouraging the use of its limbs. Swings or push-bikes, under-water exercises, etc., are more useful. If at all the muscles recover, they do so within 6 months to 1½ years and after that period, the chances of recovery are meagre. Now it is our duty to assess the muscle power very accurately and to know which group is paralysed. The deformities may be due to muscular imbalance - e. g. the foot-drop may be due to paralysis of the leg extensors; claw foot may be due to a contracture of the tendo-achilles; inverted foot may be due to paralysis of the peroneal muscles with over-action of the tibialis anterior and posterior. These sort of simple deformities are easily correctible. Splints are prescribed to prevent further deformities and contractures. Surgery is undertaken when the child is grown up, e. g. 9 years.

Likewise we often see cerebral palsied children. All cases do not carry a gloomy outlook. A majority may have to be nursed in an institution, but there is definitely a small group with minimal deformities easily

correctible by any one of the orthopaedic procedures. We should be guided by the intelligence of the patient more than by labelling him as cerebral palsy for whom nothing can be done.

The following case will illustrate my points: An young boy aged 23 years with an inelligence quotient of 70%, had adduction and internal rotation of his thighs with equinus deformity of his feet. It was a spastic type with minimal disability. Up till now the patient has been nursed by his fond parents by feeding, clothing and washing. It is too hard a job even for his parents to do for such a long time, for he is not a baby any more. In spite of medical consultation elsewhere, the advice was that nothing can be done. When I saw the boy with such a level of I. Q., minimal deformity, I felt confident that I can make him ambulant with some surgical correction and finally with a walking caliper. So a bilateral adductor tenotomy combined with achilles tendon lengthening will be more than sufficient and it was done in Madras and the patient is fast improving under the able guidance of a physiotherapist and a social worker and the surgeon.

I can enumerate many more cases of this nature of mild cases which were refused treatment for no fault of the patient. I wish to point out to you that a correct judgement of the case is possible only by a correct assessment that comes out of knowledge of the recent trends in the treatment of paralytic affections. It is high time that we in this state of Madras have an institution manned by a surgeon, a physiotherapist, a speech therapist, social workers and splint makers for the rehabilitation of all sorts of crippled children. There should be a separate department to deal with paralytic bladders and many a soul can be made to live well and tolerably better than they are today by, a skillfull team of workers.

Traumatic conditions: Supracondylar fractures of the humerus in children present a few problems in the immediate present and also late after reduction and immobilisation. Everyone of us is concerned with the huge swelling around the elbow and sometimes an absent radial pulse. The huge swelling is due to soft tissue injury with extravasation of blood and it is a barrier for proper reduction. Here I usually employ 500 units of hyalase injected locally into the haematoma area and then closed reduction under an anaesthetic is tried. If the radial pulse is absent and the swelling of the whole hand increases with signs of volkmann's ischaemic contracture, namely pulselessness, pallor, pain and pareaesthesia, then it is an urgent indication to explore the artery in the cubital fossa and to assess the real nature of the injury to the brachial artery. Sometimes it may be due to a spasm of the artery in which case perfusing the area with saline or morphine solution will relieve it, or the artery may be kinked between the fractured fragments, when you have to release it and satisfy yourself that pulsations reappear. Once a closed reduction of the fracture is done, is it always necessary to give a plaster slab? One is better guided by the swelling that is present – if the swelling is enormous, I put a compression type of bandage with three layers of cotton wool and the arm kept in a sling or kept elevated. It is good to remember some other way of treatment like that of Mr. Attenboroughs who does not try to correct the fracture in absolute anatomical reposition

that is often said to be achieved, but leaves the lateral displacement as it is, if it has not got corrected in the manipulative manouevre, because he believes that in children remoulding is great and deformity gets corrected by a process of remodelling. After six weeks, encourage active exercise only. Passive or forcible stretching should be avoided for the fear of myositis ossificans traumatica.

Ankle Sprains: Barring fractures around the ankle, another common complaint is weak and unstable ankle due to sprain or twisting injury. It may be the result of inadequate treatment in the initial stages or not treated at all. Patients come to us either for a painful, tender swelling below the malleolus or in an old case she may complain of giving way of the joint while walking. These cases are best treated with stirrup strapping, with adhesive plaster instead of immobilising the leg by a below-knee plaster of paris cast for 6 weeks. With stirrup strapping, the patient rests for 2 or 3 days and can be ambulant later and the strapping is kept on for 3 weeks and renewed if it gets loose. I have treated scores of cases with this type of stirrup strapping and convinced of its value, make bold to suggest to you. The strapping is always done by zinc adhesive plaster and never with elastoplast which gives a springing action and recoil on movements and can never keep the ankle joint without movement. An adhesive plaster is firm and is as good as plaster of paris. It is done by asking the patient to sit on a bench with the injured limb extended and a length of ordinary bandage cloth is given to him. The bandage is passed round the ball of the foot and he holds it pulling both ends like a horse's stirrup, Thus the limb is in good dorsi-flexion and erect. A 2″ wide adhesive is wound round starting from the ball of the foot in a regular circular fashion leaving no gap in between extending as far as the calf. Felt pads are placed just below the malleoli to cover the hollow spaces.

Hand Injuries: Hand is the bread-winner for an individual and due respect must be given when it is injured. The extremely delicate mechanism of movements of the hand is worked by numerous small muscles and tendons. When one of them is injured, it not only fails to work, but also impairs the efficiency of others working. In western nations where industrial work is great, these hand injuries are commoner and are treated separately in hand clinics. Volumes of work have been done and written, thanks to the pioneering work of Mr. Sterling Bunnell. A prerequisite for treating hand injuries is a correct assessment of the extent of the damage to the nerves, vessels and tendons. Even a trivial injury must be treated with respect; a slight chance for infection spreads like wild fire resulting in contractures and useless limbs. So every injured person is taken to the operation theatre and under a general anaesthetic the wound is scrubbed and cleaned with an antiseptic lotion like cetavalon and spirit A pneumatic cup tourniquet to the arm should be applied to work in a bloodless field. In a lacerated injury all available skin must be saved, they should not be trimmed. Any deficit must be covered by Thiersch skin graft which prevents infection and aids epithelialisation. The nerves should not be repaired primarily because of the physiological concept that a secondary suture after a lapse of 2-3 weeks would be very successful. If nerves are sutured primarily, there is a

chance of opposing a nerve end to a tendon. The opposed fimbriated ends of a nerve look like a cauliflower and that is no good for proper healing. The tendons in the fingers and in the palm should never be repaired primarily if you can help it. It is absolutely mandatory to apply a correct type of dressing for the hand with a compression bandage in the palm in the position of function as though the hand is gripping a cricket ball in the hollow of the palm. The tips of the fingers are left uncovered to enable movements. The hand must be kept elevated to prevent oedema which will prevent proper healing. Prophylactic antibiotics like penicillin must be started from the beginning to ward off catastrophic infection.

Treatment of Skeletal Tuberculosis: One day one of my friends challenged me on the value of operations like costo-tranversectomy and antero-lateral decompression for tuberculosis of the spine. He cited two cases of Pott's spine in the mid-thoracic region with paraplegia which improved astonishingly with simple recumbency on a plaster shell and streptomycin therapy. I will endeavour to show you that orthopaedicians do not go by a rule of the thumb in such cases as Pott's spine. Conservative regime becomes very successful when combined with operative intervention in certain well selected cases. We do not advise operation for all and neither conservative treatment for all. I interviewed all the bone tuberculosis cases in the wards of the Government Erskine Hospital and very many of them have stayed too long in hospitals – 9-15 months and a few are re-admitted for the 2nd or 3rd time for the same complaint. I fully agree with the value of constitutional treatment and streptomycin has most certainly turned a new era in the successfull management of skeletal tuberculosis; but it has, in addition, given us the courage to dare and operate early whenever it is indicated and thus facilitate early ambulation and return to normal work. It would be a very grave error to ignore operations. In cases not operated, complications like miliary tuberculosis, meningitis and septic complications with a late mortality of 16% as compared to 70% in operated cases. (Harris and Coulthard JBJS 1942–24–382) These authors followed 296 patients for 1–10 years and found 85 had died from miliary tuberculosis.

In a tuberculous lesion there is a local endarteritis and ischaemic necrosis in the earliest stages. Once this has occured, antibiotic drugs can only reach the affected part with difficulty, unless the way is opened by a currettage of the necrotic foci. By virtue of the blood supply and free vascular connections for the synovial membrane, capsule and epiphysis, there is always a concomittant infection of the synovial membrane. M. C. Wilkinson (J B J S 1953 - 35b - 211) has verified this by operations that even after giving streptomycin for 90 days, in no case was the synovial membrane normal. The synovial membrane regenerates after removal and, therefore, partial synovectomy accompanied by antibiotic treatment affords an opportunity for fresh and healthy synovial tissue to be developed along with fresh blood vessels which will bring the anti-biotic into the diseased area.

In the treatment of Pott's spine, the constitutional treatment takes precedence with recumbency on the anterior or posterior plaster shell combined with streptomycin therapy. The

results are gratifying in the early cases when it is detected. Bony union is common in lower lumbo-sacral region. In mid-thoracic and lower thoracic regions where most cases are present the problem is viewed studying each individual case with its salient features. Once a paravertebral abscess has formed, unstable ankylosis occurs in 45% of cases. Paraplegia occurs in 10% of cases, but all cases in the hospital are paraplegic because they only get admission into the hospitals for want of enough space. Here we start the usual conservative regimen till we see a satisfactory improvement in the recovery of paraplegia within eight weeks. Once it is observed that the disease is not limiting, but progresses even after 8 weeks of conservative treatment, it is absolutely obligatory to evacuate the pus by antero-lateral decompression. The posterior spinal fusion is also indicated after 2-3 years, when the disease has settled down, because healing is always by unstable ankylosis. So we see that it may be that a great majority of the cases become quiet by plaster immobilisation and streptomycin, but there is a definite group of patients who do not respond to recumbency treatment, when paralysis steadily increases and degenerates and their only hope is operation. The above views are applicable to our present state of affiairs, but it is not the latest trend where Seddon and Griffiths advise operative evacuation of tubercle foci in all cases with cancellous bone packing. They claim speedy recovery with mobile joints.

Course and end-result in skeletal tuberculosis : Often the parents or the patient puts a barrage of questions like : How long I have to be in bed or plaster ? How many injections should I have ? Will I be able to use my limb as before ? These are very difficult questions to answer, because the answer depends upon the joint that is involved and the associated complications that exist. We are faced with a problem-when shall I say the lesion is healed ? We shall answer them like this. The patient is in bed with immobilisation till there is definite improvement of the general health, viz. no fever, good appetite, weight increase, no local pain or swelling or abscess formation. Enforced rest favours an undisturbed and smooth course of the disease and it provides the chance for the natural forces of repair to operate without interference. In other words there must be clinical evidence of beginning recuperation, corroborated by the x-ray. In weight-bearing joints like the hip, weight-bearing is not allowed strightaway, unless there is good reactive sclerosis of bone to resist impaction so that the patient can be made ambulant with Thomas leg splint or plaster and with the help of crutches. The return to normal function in a given joint is a matter of past observation. In the spine, as dealt earlier, bony consolidation in the lumbo-sacral region is possible, in mid-thoracic and lower thoracic region after abscess formation, there is unstable ankylosis and so it requires spinal fusion. In the hip in the early stages operation of curettage and bone-grafting is done; a mobile hip is possible, otherwise bony ankylosis is the result. In knee the only definite cure for a T.B. knee in the adult is the operative fusion and in synovial type also partial synovectomy is indicated. In the ankle, a freely movable ankle is possible. In the elbow in adult full mobility is a rare exception ; after a period of conservative treatment,

operation to arthrodese the joint is essential, whereas in children there is a considerable tendency for repair. All these do not mean avoidance of conservative treatment in the early phase.

Tumours: I am not going to deal with the pathological or histological appearances of bone tumours. I want only to stress the importance of the relationship of trauma to the tumours. Most of the tumours occur near the ends of the bone and the patient has no difficulty until the joint gets involved. The diagnosis is obviously made when the patient presents with a fast-growing bony swelling with pain. In the earliest stages the patient notices a small swelling at the site of the trauma which he ignores or gets it treated as a haematoma. As the swelling increases in size, the diagnosis of a tumour must be thought of at this stage and should be confirmed by a radiograph. The treatment of bone tumours can be entrusted to the specialist.

Conclusion: It is said, "what mind does not know, eyes do not see". Hence I selected a few important conditions which we can diagnose and treat early, when we bear them in mind.

10th MADRAS STATE OPHTHALMIC CONFERENCE, AUGUST 1962, KUMBAKONAM.

You will be pleased to know that the 10th Madras State Ophthalmic conference will be held on the 11th and 12th August, 1962 at the **Town High School Buildings, Kumbakonam.**

Dr. P. Ramchandar of Hyderabad has kindly consented to preside over the sessions of the Conference.

It would be a great pleasure if you kindly make it convenient to participate in all the functions connected with the conference.

A trip round Neyveli Lignite Corporation is being arranged to give an opportunity to the delegates to visit the biggest industrial project of the South.

May I request you to be kind enough to send me any scientific article for the Souvenir to be published and also read papers in the Conference. The articles and papers may kindly be sent to me before the end of May, 1962. A panel discussion on the common problems of ophthalmic practitioners is also being arranged. I would be thankful if you can let me have the questions and doubts for the discussion early enough for inclusion in the agenda.

Soliciting your active co-operation for the successful conduct of the Conference.

R. Mahalingam.

REVIEW

Gevaert X-Ray Bulletin (2–1961.) We have received an attractively brought out x-ray bulletin by M/s. Gevaert.

Dr. Hans Vogler, x-ray physicist in an interesting article has given a brief description of the characteristic curve of an x-ray film and how it can be used for evaluating its quality and thus compare two or more types of films, so that a radiologist can decide which would be the best for a particular purpose. The instructions are given in a simple and clear way how to read the curve to get the correct values of the properties of a film.

Prof. J. R. von Ronnen and J. D. Mulder from the department of Radiology of the University of Leyde, Holland, gives the results obtained with a new aorto-arteriographic apparatus. This apparatus enables one to obtain one continuous picture of the lower part of abdominal aorta, the arteries of the pelvis and the lower limbs.

The apparatus consists of a movable platform on the x-ray stand, a cassette holder with a changing elevating mechanism, The size of the cassette is 14″ × 28″, each cassette holding two ordinary films of 14″ × 14″. The patient is automatically moved once during the examination a distance not more than 28″. A very good photograph of the apparatus is given with illustration of its various parts. Skiagrams of four cases showing the aorto-arteriograms are also given.

Dr. M. Gilson, Assistant to Prof. R. Weekers from the Ophthalmological Clinic of the University of Liege has given a short description of the technic of colour photography of the fundus of the eye, with illustrations of eight fundi. The essential things for success in getting a clear picture of the fundus are :

1. Electronic flash which gives a very bright light of a very short duration of the order of a thousandth of a second.
2. Pupils must be fully dilated.
3. Correcting lenses inserted into the apparatus to compensate for ametropia of the subject's eye.

The retinal camera gives a flat field image over about 30°, over a circular field 22 m.m. in diameter. This will be very useful for the physician to study the condition of the retinal vessels in various diseases.

We are sure that this 'Bulletin' would be enthusiastically received not only by the radiologists and ophthalmologists but also by the practitioner who will be interested in the advances in the field of radiology and medical photography.

The 'Bulletin' is distributed in India by M/s. Allied Photographics Private Limited, Kasturi Building, Jamshedji Tata Road, Bombay-1.

— *Rithuparnan.*

SOME VASCULAR DISORDERS AND THEIR OCULAR MANIFESTATIONS*

K. S. SUBRAMANIAM, B. SC., M. B., B. S.,
D. O. (Madras & London), F. R. C. S. (England),
Assistant Professor of Ophthalmology and Head of the Department
Medical College, Calicut.

Ophthalmology tends to get only scant attention during the medical curriculum. It is quickly learnt for the examination and is as quickly forgotten. Consequently, in practice, the knowledge in this subject of most practitioners is limited, and they have only a nodding acquaintance with it. I do not intend, therefore, discoursing tonight on purely ocular diseases which are of interest mainly to the ophthalmologist. I have chosen a more broad-based subject which I hope will interest both the oculist and the practising physician, namely, "Some vascular disorders and their ocular manifestations"

The two commonest general vascular disorders which produce ocular complications are: (i) Arteriosclerosis. (ii) Hypertension.

Before we attempt a survey of the changes in the ocular fundus in these diseases, it would be useful to recapitulate the salient features of the normal fundus. The ocular fundus presents for ready inspection the optic disc, which is pink in colour, appears to be about 1½ cm. in diameter, has clear-cut margins and shows in the middle a pale yellow depression called the physiological cup. Through the middle of this cup enters the central retinal artery which breaks up into four branches—the superior and inferior temporal and nasal retinal arteries. The central retinal artery is an end-artery. Accompanying the branches of the artery are the tributaries of the central retinal vein, which is formed by their union at the disc. The arteries can be distinguished from the veins by the fact that they are paler and narrower. The diameter of artery: vein is 2:3. From the surface of the artery and vein, the light that is shown on the fundus reflects back as from a convex cylindrical mirror. This linear light streak on the vessel is called the vascular light reflex. It should be remembered that what is seen of the vessels is not their wall which is transparent, but the contained blood column. At the arterio-venous crossings (A/V), the artery and vein have common adventitious coat, and the artery, which usually lies superficial to the vein, shows through its blood column the underlying venous column which is neither compressed nor deflected. Temporal to the optic disc, about two disc diameters away, is the macula lutea, which is the site of most acute vision. The area of the fundus surrounding and including the optic disc and the macula is commonly referred to as the posterior pole of the fundus and it is here that most of the important changes occur.

In arteriosclerosis, the earliest visible changes are a broadening of the light reflex from the arteries, which gives

* Address to the Coimbatore District Medical Association on Sept. 16, 1961.

them a tarnished copper wire appearance. The smaller branches may show tortuosity; micro-aneurysms may be present. Because the wall of the artery looses some of its transparency, the underlying vein at the A/V crossing may not be visible. The vein may appear to be compressed. If there is actual compression of the vein, the proximal part of the vein appears dilated and tortuous. The vein may be slightly deflected from its original course. Alteration in the light reflex and A/V crossing changes are the earliest visible ophthalmoscopic manifestations of arteriosclerosis. The thickening of the arterial wall tends to be progressive. It becomes white and sheathed, when it is said to have a silver wire appearance. Indeed, in the late stages, blood in the artery may not be visible at all, and it may look like a fibrosed cord. These vaso-sclerotic changes diminish the amount of blood carried to the retina. Consequent on this ischaemia, hyaline and lipoid degenerative material is deposited in the substance of the retina as hard white "exudates" near the retinal vessels. Superficial flame shaped retinal haemorrhages may also be seen, and this fundus picture of vascular changes with exudates and haemorrhages constitutes arteriosclerotic retinopathy. The general blood pressure may be raised, or only the systolic pressure may be raised. The importance of recognising this condition is that when such changes are present in the retina, they are nearly always present in the cerebral, coronary and renal vessels also. It is, therefore, the duty of the physician in these cases to periodically check the efficiency of the cardiac, cerebral and renal circulation.

In hypertension, which usually manifests after middle age, there may be arteriosclerotic changes as well. The hypertensive manifestations are: Narrowing and straightening of the retinal vessels; irregularity of their calibre; A/V crossing changes as in arteriosclerosis; superficial flame-shaped retinal haemorrhages; and, when oedema of the retina occurs, it manifests as small, soft, ill-defined white, multiple cotton-wool exudates around the disc. In the later stages, the oedema of the macular region may be so great as to raise the internal limiting membrane into folds to form a macular fan or star. This gets consolidated and hardened as multiple small hard spots of exudates arranged like a fan at the macula. Coincident with this, oedema of the optic disc may be seen. This is the final and most severe stage of hypertensive retinopathy and since the outlook for life at this stage is poor, the hypertension is said to have passed from the benign to the malignant stage. It is important to remember that vision may not be affected until the macula is involved and the patient may actually seek the advice of the eye specialist regarding dimness of vision when he has the full blown picture of malignant hypertensive retinopathy.

The different stages of the retinopathy have been graded according to the fundus pictures by Keith, Wagner and Barker after studying a large series of cases and following them up. Grading helps in assessing the prognosis and the effect of treatment. According to these workers, in grade I there is spasm of the retinal vessels; grade II shows A/V crossing changes in addition; in grade III there are also superficial retinal haemorrhages and soft, cotton-wool exudates; grade IV shows papilloedema in

addition, and indicates malignant hypertension. In an eight-year study, they found that the prognosis in grade I, in terms of eight-year survival, is 98% ; in grade II-80% ; in grade III - 30% ; and in grade IV, untreated cases die within a year. These fundus changes in hypertension, specially in grades III and IV, indicate severe retinal involvement and there is, therefore, albuminuria, casts in the urine and a pronounced rise in blood pressure. With treatment with either ganglion blocking agents or surgery or both combined, it is nowadays possible to control the blood pressure in most cases and when controlled, the retinopathy tends gradually to disappear. The retinopathy of hypertension is, therefore, a constantly changing picture and periodical fundus studies would appear to be of value in hypertensives.

The two common local vascular diseases are: 1. Central Retinal Artery Occlusion (C. R. A.). 2. Central Retinal Vein Thrombosis (C. R. V.).

1. In *central artery occlusion,* sudden complete painless loss of sight occurs. Usually only one eye is affected ; such a catastrophe occurring in the other eye, though possible, is rare. Examination shows a widely dilated fixed pupil and the fundus, if seen within a few hours or a day after the occlusion, shows markedly narrowed thread like retinal arteries and oedema of the retina from albuminuous degeneration. This is seen as a white patch around the macula and the macula itself being very thin shows the underlying choroid through as a cherry-red spot. This fundus appearance is so characteristic that once seen, it cannot be missed again. The chief underlying cause is atherosclerotic changes in the central artery at the optic disc. In this situation the artery is slightly narrower than in the rest of its course and thrombotic occlusion at this site is the cause in 98% of cases. Rarely, an embolus may be the cause as in mitral stenosis or in sub-acute bacterial endocarditis, where it is seen more on the left side than on the right. Rarely, spasm also is a factor which may help to make a partial occlusion complete. In the majority of cases, treatment is of no avail. Retro-bulbar injection of 1 cc. of priscol or acetylcholine may help to relieve the spasm and dilate the blood vessels and thus help to increase the blood flow; or, in the rare embolic case, help to shift the embolus to a peripheral and less important branch of the central artery. Paracentesis has also been tried. Lately, in an effort to increase the amount of oxygen carried to the retina, if the artery is still carrying a thin stream of blood, patients have been given oxygen mixed with carbon dioxide and in a series of over thirty cases, four or five seem to have had some benefit. Whether the oxygen administration was really the cause of improvement, it is not possible to say, but it is worthwhile combining this with vasodilators in a larger series of cases to find out its value. Since in the absence of treatment vision is completely lost, no method of treatment should be lightly discarded without adequate trial.

One type of unilateral visual loss, which is luckily usually transitory and associated with contralateral hemiplegia, is internal carotid artery occlusion which is more often left-sided. In these cases the internal carotid artery in the neck may not show pulsation, if the occlusion is relatively low and near its origin as it usually is. The main cause again is atherosclerosis, though syphilis,

lumps in the neck and injuries may also involve the artery in the neck. Because of the fairly efficient vascular anastomosis between the radicles of the two internal carotid arteries, permanent damage to sight occurs in only a small percentage of cases. Diagnosis can be confirmed by carotid angiography and, if possible, a segment of the diseased artery may be replaced surgically by an arterial graft.

2. *Central Retinal Vein Thrombosis* occurs in elderly atherosclerotic individuals, a good many of them being also diabetic. The occlusion occurs at the lamina cribrosa and as a result the retinal vessels are grossly enlarged, the fundus around the disc is splashed with multiple retinal haemorrhages and some white exudates and if the haemorrhage involves the macula, central vision is markedly diminished. The fundus is said to show a stormy sunset appearance. Gradually the haemorrhages and oedema get absorbed, but in about one third of the cases owing to the development of a vascularised membrane at the angle of the anterior chamber owing to some obscure cause, an intractable secondary glaucoma results and the eye is lost. When such venous thrombosis occurs, systemic treatment with anticoagulants should be started not only to prevent the thrombotic process spreading backwards, but also to prevent its occurence independantly in the brain or heart.

Vascular abnormalities inside the cranial cavity are also not rare. In order to understand the ocular manifestations they produce, a brief survey of the cerebral vascular system and the visual pathway is essential.

The cerebral circulation stands on four legs—the two internal carotid arteries in the front of the neck and the two vertebral arteries at the back of the neck. These enter the skull and form a vascular ring of anastomosis called the Circle of Willis from which branches supply the brain and the eye. The anterior part of the Circle of Willis is disposed above the visual pathway; the posterior part below it.

The visual pathway consists of the two optic nerves, which passing backwards through the optic foramina into the skull unite over the sella tursica to form the optic chiasma, where the medial retinal fibres decussate, but not the lateral fibres. The lateral fibres of the same side and medial fibres of the opposite side pass further back as the optic tract, ends at and relays at the lateral geniculate body, and fresh fibres from here pass partly through the parietal and partly through the temporal lobes of the brain as the optic radiation, to reach the visual cortex in the occipital pole, on either side of the calcrine fissure.

Involvement of the optic nerves on the one or the other side produces varying effects on the vision of that side only. Lesions at the chiasma usually produce by pressure bitemporal hemianopia. Lesions above the chiasma produce homonymous hemianopia. Tract lesions are differentiated from radiation lesions by the fact that the pupil reaction is unaffected in the latter, by slight differences in the hemianopia and other localising signs.

The most important cranial vascular abnormalities are aneurysms of the Circle of Willis. Many of these are small and silent, and people are

unaware of it. But some become large, may leak or rupture, and produce dramatic symptons. The aneurysms may be congenital, syphilitic or traumatic in nature.

Anteriorly situated aneurysms affect either the optic nerve or the chiasma. An aneurysm of the anterior cerebral or anterior communicating artery may by pressing on one optic nerve produce ipsilateral optic atrophy with blindness on that side; by raising the intracranial pressure, would produce papilloedema of the opposite side; this is known as the Foster Kennedy syndrome. Anterior communicating artery aneurysms, however, usually produce the chiasmal syndrome. An aneurysm of the anterior cerebral artery at its commencement may press on all the oculomotor and sensory nerves as they pass through the superior orbital fissure producing immobility of the eyeball and ptosis and anaesthesia of the eye and neighbouring face. This is the superior orbital fissure syndrome. Middle and posterior cerebral artery aneurysms by implicating the visual pathway behind the chiasma produce homonymous hemianopia. The internal carotid artery has a long intracranial course in the skull and may suffer aneurysmal dilatation. These may be either supra or subclinoid, the latter being usually inside the cavernous sinus. As it becomes larger, pressure symptoms are produced like third, fourth and sixth nerve palsies. If posteriorly situated in the cavernous sinus, all the three divisions of the fifth nerve are involved. If anteriorly situated, the mandibular and maxillary divisions may escape. Occasional leaks of the anuerysms produce intense unilateral headache over the side of the leak and external ophthalmoplegia of varying degree. These may recover, but further leaks may lead to permanent oculomotor palsies. This is often miscalled ophthalmoplegic migraine.

A ruptured anuerysm of the internal carotid artery in the cavernous sinus produces a cortico-cavernous aneurysm with a characteristic clinical picture. The patient complains of a severe one-sided headache, redness of the eye, dimness of vision, and rumbling noise in the head like a waterfall. Examination shows a pulsating exophthalmos, dilated veins on the scalp, forehead and eye of that side, and a bruit may be heard on the head. Diagnosis may be made by plain x-ray (erosion of the clinoid processes) and angiography. The diagnosis of intracranial vascular abnormalities has been greatly, helped by the introduction of angiography by Egaz Moniz of Lisbon in 1929. By taking serial x-rays in the arterial, capillary and venous phase, many lesions can be located. Treatment is ligation of the internal or common carotid artery of that side.

Rupture of an intracranial aneurysm in any other situation produces the signs of subarachnoid haemorrhage. This is fatal in 50% of cases; recurs in four weeks in half the remaining cases, of which again 50% die. As a result of this, oculomotor paralysis, papilloedema and subhyaloid haemorrhage are seen in the eye. The treatment is the province of the neuro-surgeon. Cerebral haemorrhage from other causes like arteriosclerosis, hypertension, bleeding diseases, etc. produce headache, vomiting, unconsciousness; if the patient survives, papilloedema, homonymous hemianopia and a dilated pupil on the affected side are seen. A pontine haemorrhage produces pin-point pupils. Other manifestations may be loss of corneal reflexes and supranuclear muscle palsies.

Cerebral angiomas usually occur on the convexities of the cerebral hemispheres. They may be small or large; silent or symptomatic. The usual symptoms are migrainous headache, focal epilepsy, hemiparesis, bruit and dementia. In this connection it should be mentioned that a congenital naevus of the face on one side may be associated with an intraocular choroidal angioma, producing anophthalmos and intracranial angiomas in what is called the Shuge Weber syndrome.

Migraine may also be included, since it is considered as being due to a vascular diathesis. The main symptom is unilateral headache which may occur in one or the other side, preceded by a transient visual aura, consisting of a homonymous hemianopia with a display of flashes of colours in the scotomatous areas, therefore called fortification spectra. This is followed by severe unilateral headache on the side opposite to the scotoma, which may be so incapacitating as to produce vomiting and prostration. This lasts for a variable period after which the headache disappears. It is believed that vasospasm in one cerebral hemisphere produces the aura and the vasodilatation which follows produces the headache. Various ergot preparations and tranquillisers have been tried symptomatically. Errors of refraction have been checked and foci of sepsis removed in many cases, but nothing is known of the cause and I would like to learn from my more experienced ophthalmic colleagues in this audience their views on this obscure but not uncommon condition.

I would, however, like to emphasise that any migrainous headache which occurs always on the same side should make one suspect an aneurysm or angioma on that side of the skull and diagnostic measures should be undertaken to exclude such organic cause for the headache in these cases.

Two rare diseases which I would finally touch upon are temporal arteritis and pulseless disease. The former occurs in the elderly and affects not only the temporal arteries as the name suggests. but also the intracranial arteries as well, and produces various neurological signs including ocular muscle palsies, various bizarre field defects, and occasionally the central retinal artery may be occluded. Pulseless disease mainly affects the young and the main arteries of the head and neck are involved leading to cerebral and ocular ischemia. Fainting attacks, giddiness, hemiplegia or hemianaesthesia, dimness of vision and cataract may occur as a result. Most case reports of this disease are from Japan and one view of the cause of the disease is that it may be one form of syphilitic aortitis with gradual occlusion of the origin of the arteries from the aortic arch.

I am afraid I have taken more than the time alloted to me to tell you in bare outline of how some vascular diseases can produce ocular manifestations and how a study of the eyes in these cases can be helpful. I have no desire to prolong this further, but would humbly suggest to you that the ophthalmoscope may be used more often to look into the eyes. It is not difficult to learn to use it, and the study of the fundi would pay rich dividends. I think I would be right in saying that we are very ready in using the stethoscope, less ready to use the tendon hammer, or blood pressure apparatus, and hardly ever think of the ophthalmoscope. I believe that the ophthalmoscope is as valuable a diagnostic "weapon" as the others mentioned.

ACUTE ABDOMINAL EMERGENCIES IN INFANTS AND CHILDREN*

C N. SANTHANAM, M. S., Coimbatore.

INTRODUCTION :

Difficulties in diagnosis : Diagnosis of the acute surgical conditions of the abdomen in infants and children is difficult. The natural history of the disease in these age groups differs from that in the adult mainly in the rate of progress. So diagnosis is a more urgent problem and the delay is fraught with danger. Diagnosis is difficult because children are generally unable to give a subjective history and the information obtained from the parents is most often coloured by emotion. Another factor which contributes to the difficulty is that a child reacts to disease process differently from an adult. For example, vomiting occurs more readily in children and their reaction to pain is variable. Some lie quiet, some others whine and whimper, and others even shout. They have often diarrhoea with a condition which in adult is associated with constipation. High fever is common apart from acute infection. Localised tenderness and rigidity are often absent.

The abdominal pain may be of three types :— (1) The constant ache of distention, whether this be of a single loop of intestine, of the colon, or of the whole abdomen. (2) A severe ache accompanied by fever arising from inflammatory process which is usually sufficiently localised for the patient to indicate its position. (3) The colicky pain of muscle spasm whether this be due to inflammation or obstruction and whether it is in the biliary tract or the alimentary tract or the urinary tract. Children over the age of 6 years are usually able to give a fairly accurate description of the pain when questioned. Infants and toddlers are unable to do this ; and to them any pain and every pain is only a 'head - ache' or a 'belly - ache'. In these, generally, there are different types of reactions to the different types of pain. For example, the pain of distention is indicated by whimpering, anorexia, and frequently pallor produced by and associated with nausea. The second type, i. e. the severe aching pain of inflammation is associated with fever and usually with drowsiness, crying and irritability when disturbed. The third type is manifested by screaming attacks of colic and pallor.

The difficulty in diagnosis is also increased by three confusing factors :

(1) Diarrhoea.
(2) Entro-mesenteric lymph field.
(3) Extra-abdominal lesions.

In childhood *diarrhoea* may be the herald of any acute abdominal lesion. It may be one or two extra loose motions. On the other hand vomiting, extreme tenderness and board-like rigidity may be the fore-runners of an impending infective diarrhoea. This can be differentiated with the aid of a stethescope. Excessive peristalsis will cease soon after the onset of

* Based on a lecture delivered at the Tiruchi District Medical Association 32nd Annual Meeting held on 29—10—1961.

pain in acute appendicitis, but will be vigorous in the developing enteritis. Vigorous peristalsis will exclude a diagnosis of perforation.

The second confusing factor is the reaction of the *lymph glands* in the mesentery and the lymph follicles in the bowel. In childhood most of the infective fevers are associated with involvement of the mesenteric lymph glands and lymph follicles in the bowel and appendix. Measles and strepto-coccal infection of the throat are the two common conditions in which abdominal lymphadenitis is also present and mistaken for acute appendicitis; but unfortunately in a few cases of measles or acute tonsilitis there may be real mischief in the appendix. Only the presence of other enlarged lymph glands or Koplick spots or sore throat will help us to differentiate. In these cases it is really safer to explore when in doubt, than to leave a fulminating appendix complacently. Deep iliac adenitis due to septic lesions on the legs or buttocks can also simulate acute appendicitis.

The third confusing factor is the hidden mischief away from the actual site of pain, i. e. *the extra-abdominal lesions* producing pain similar to acute lesions in the abdomen. Hence careful examination of the whole child is very necessary.

EXAMINATION OF THE PATIENT:

I am sure it is unnecessary on my part to impress on you that the examination of the child requires gentleness and patience. The examination should be done in comfortable and warm conditions and in quiet surroundings. History of the onset must be obtained from the parents directly. Then the child is examined in a systematic manner. Pulse and temperature are recorded. The ear drums are inspected for any signs of inflammation or accumulation of wax. Throat and rectal examinations are better postponed towards the end to avoid frightening the child and producing retching. Inspection is valuable for a feeble cry, pallor, loose skin and parched lips with green vomitus indicate severe illness. Abnormal peristalsis and bowel distention are easily observed through the thin abdominal wall of an infant. The abdominal wall may not move at all. When questioned where the pain is, he may point to the umbilicus or sometimes to a particular side which may implicate the kidney. The hernial orifices must be examined in all cases of acute abdomen. If the child resents being moved or turned over, it is an indication of a serious mischief. A baby's napkin or toddler's nickers might hide the cause of acute abdominal distress. Paraphimosis, ulceration of the urinary meatus, torsion of an ectopic testis or of tiny congenital cysts on the testis or epidydimis, can each simulate peritonitis. A septic toe or an infected abrasion on the knee or lesions on the buttocks may give rise to deep iliac adenitis, the primary lesions may, however, have healed.

As you all know well, the hand palpating the abdomen should be warm and the palpation should start first away from the suspected site of lesion. Gentle palpation gives information that is completely lost to the heavy handed. A child who is known to be of good temperament, who feels restless and irritable when approached and who refuses to allow the abdomen to be touched is really a suspect. May be he is harbouring a ruptured appendix and his abdomen is full of pus. Examination of the chest will eliminate a basal pneumonia, and

when in doubt, an x-ray of the chest will eliminate it. Rectal examination must be done and done gently. The child's apprehension should be overcome with gentle assurances. It is rather a curious fact that in most cases of acute abdomen the yelling child becomes quiet soon after the finger is inserted. If the rectum is loaded, a simple warm water enema should be given and the rectum examined again. In an empty rectum the pouch of Douglas could be palpated. A pelvic appendix or a stone in the bladder could be palpated by this *manouvre*. The lower abdomen should be palpated bimanually with a finger in the rectum and a hand on the abdominal wall. If this could be carried out without any discomfort to the child, then it can safely be assumed that there is no serious lesion in the lower abdomen. The throat should be examined with a good light and without hurting the child and inducing retching.

Urine should be examined microscopically for pus cells, for pyelitis is a frequent cause of pyrexia and pain in children. The leucocyte count, although helpful, is not a diagnostic guide in the acute abdomen of the children as in the adults.

Abdominal roentgenograms are helpful in establishing the diagnosis of intestinal obstruction as well as perforation. By using the newer water-soluble radio-opaque materials instead of barium, one can almost pinpoint the actual site of obstruction.

In considering the indications of surgical intervention, the primary decision is whether the child should be removed to an institutiou or treated in the house itself. This decision has quite often to be taken before an accurate diagnosis can be made. When there is substantial doubt, it is safer to get the child admitted. This is a wise and safe decision because of the appalling conditions in which most of the less affluent live in our country. Economic considerations and environmental conditions preclude a child being observed in the house constantly or frequently by the attending physician. But many of the non-surgical and extra-abdominal conditions could be treated at home — at any rate to those who could afford it — and thus the ever increasing problem of congestion in the hospitals and ever present risk of hospital infection could be avoided.

NATURE OF LESIONS:

Abdominal emergencies in childhood vary with the age group. There are three well defined periods, namely (1) the neonatal period, (2) the period before the child can talk or express itself, and (3) after that time. The lesions that produce acute surgical abdomen are not easily categorised as there may be an overlap in the above three periods. Generally speaking, the following lesions are met with:

A. In the new-born infants and in the first few weeks of life:

(i) Developmental defects such as omphalocele.

(ii) Atresia and stenosis of the gastro-intestinal tract.

(iii) Diaphragmatic hernia.

(iv) Malrotation of the intestines.

(v) Meconium ileus.

(vi) Imperforate anus.

(vii) Congenital hypertrophic pyloric stenosis which is not met with before the infant is a few weeks old.

B. In the first year of life:

Intestinal obstruction secondary to intussusception and strangulated hernia in children lesser than two years old. Through appendicitis is said not to occur before two years of age, cases have been reported in the first year of life.

C. Conditions which occur in older children and throughout childhood include acute appendicitis, complications of Meckel's diverticulum, intestinal obstruction from various causes and trauma.

A. **IN THE NEW BORN INFANT:**

(i) *Omphalocele* or umbilical hernia is a defect in the abdominal wall with herniation of the abdominal contents into the base of the umbilical cord. It is covered only with peritonium and amniotic sac. Urgent repair is indicated, because the sac may rupture and peritonitis results. In small herniae, one stage reduction and complete closure is possible. But in the majority of them which are huge where almost the whole abdominal viscera including a part of the liver are inside the cord, two staged repair only is possible. In the first stage skin flaps are mobilised and the defect covered temporarily. The repair of the muscular and facial layers are done later when the abdominal cavity has enlarged.

(ii) *Atresia and stenosis of gastro-intestinal tract:* Atresia is a developmental defect in which a portion of the gastro-intestinal tract fails to canalise. In "stenosis" partial canalisation has occurred so that the lumen is only narrowed or constricted. In atresia there is complete intestinal obstruction. The bowel proximal to the obstruction is dilated and vomiting is noted on the first day of life. Atresia mostly occurs distal to the ampulla of Vater and hence the vomit contains bile; but in the rare cases it may occur proximally and hence the vomit may not contain bile. So any new-born infant which vomits on the first day of life must be suspected to have intestinal obstruction whether the abdomen is distended or not. Not only in the neo-natal period, later on also any child with bilious vomiting should be carefully investigated whether there is distention of the abdomen or not and whether the child is constipated or not. Many cases of duodenal or intestinal atresia or stenosis could be spotted earlier and treatment instituted effectively if only one takes note of this bilious vomiting.

The degree of abdominal distention depends upon the level of obstruction. In duodenal atresia, the distention is usually limited to the epigastrium or may be even absent, if the stomach has remained empty due to vomiting. When the atresia is more distal, the distention is more marked and is progressive. Roentgenogram will reveal the dilated bowel of the intestinal obstruction. After birth the baby takes its first breath and soon after this swallows its first mouth-full of air. This air travels down the intestinal canal and before 12 hours have elapsed, the infant may pass the air per rectum. If there is obstruction, the site at which the air is held up is often clearly visible in the plain x-ray picture. This is particularly true of duodenal atresia where the x-ray shows marked distention of the duodenum. In stenosis, since the obstruction is incomplete, symptoms appear late in life and are less severe and more chronic in nature.

(iii) *Meconium ileus:* In this due to the impaction of the insipissated meconium there is intestinal

obstruction. This condition is associated with either decreased or absent pancreatic enzyme activity. There may be cystic fibrosis of the pancreas. The meconium becomes increasingly sticky and putty-like and blocks the distal ileum usually with distention of the proximal bowel. This condition should be suspected at birth if the amniotic fluid is coloured or fetid and if the abdomen is distended. Plain x-ray of the abdomen shows dilated loops of bowel and a mottled or granular appearance in areas of concentration of the insipissated meconium. Occasionally flecks of calcium are seen throughout the abdomen indicating peritonitis of foetal life. A completely satisfactory method of treatment is not available for this condition. Treatment of choice is laparotomy with one or more operative enterostomies and manual removal of the meconium. Irrigation through the enterostomy opening with saline, peroxide and other solutions have given satisfactory results in some cases. Pancreatic enzymes should be directly introduced through the enterostomy opening. Post-operatively pancreatic enzymes should be given orally for a long time.

(iv) *Malrotation of the intestines:* This anomaly occurs because the embryonic midgut which develops into the terminal ileum, caecum, ascending and mid-transverse colon, fails to complete its normal counter-clock-wise rotation after its return into the peritonial cavity during the tenth week of intra-uterine life. As a result the caecum remains in the right upper quadrant. Bands of reflected peritonium from the caecum may cross the duodenum and obstruct it. Further the attachment of the small bowel is short and rudimentary. Because of the short mesentery and lack of fixation of the right and left colon to the posterior abdominal wall, volvulus of the entire midgut may occur. When obstruction of the duodenum is present, symptoms and signs are similar to those in duodenum atresia. The vomitus is bile stained, the upper abdomen is distended and x-rays show dilatation of the stomach and duodenum. When volvulus occurs, the characteristic findings are pain, vomiting, toxemia, and abdominal distention.

Treatment consists of laparotomy and incision of the peritonial folds that compress the duodenum and thus release the duodenal obstruction. In cases of volvulus, the bowel must be de-rotated and, if non-viable, resected. It is surprising but true that the neonates tolerate a large amount of intestinal resection.

(v) *Imperforate anus:* This may be of several types varying from a membranous diaphragm to a complete absence of the anus and the rectum. Diagnosis is made by inspection at the time of birth or when the child fails to pass meconium. If the condition is unrecognised, several days may elapse before the distention and vomiting due to the intestinal obstruction occur. The x-ray of abdomen is taken with the infant in inverted position with a metal marker over the anal region. The gas shadow in the colon and rectum indicates the extent of occlusion.

Treatment is by surgery only. Even in cases with associated fistulae like recto-vaginal, recto-vesical, recto-urethral, excepting cases of recto-vaginal the other cases should be operated immediately. In recto-vaginal fistula cases, the operation can be postponed for a year with periodic dilatation of the fistula.

(vi) *Diaphragmatic hernia :* Though this is strictly not an abdominal emergency, since the hernial contents originate from the abdomen and since surgical repair is best done through the abdomen, this condition is included for consideration. In children it is usually due to a developmental defect of the diaphragm. There are three main types, namely (1) Posterolateral (Foramen of Bochdalek), (2) Hiatal and (3) Retrosternal (Foramen of Morgagni). Symptoms of dyspnoea and cyanosis are noted shortly after birth. The affected side of the chest may not move and there may be a mediastinal shift to the normal side. Auscultation demonstrates distant or absent breath sounds, but peristaltic sounds are heard clearly. X-rays of the chest and abdomen establish the diagnosis. Early recognition and repair of the hernia are essential. The operation is best done through an abdominal incision. The abdominal viscera are withdrawn from the chest and the defect in the diaphragm is repaired. It may be difficult to close the abdominal wall and hence it may have to be repaired in two stages as for a large omphalocele.

(vii) *Congenital hypertrophic pyloric stenosis :* It is a most common abdominal emergency encountered in the neonatal period. The reason for the hypertrophy of the pyloric musculature is not known and recent data suggests that it may not be even congenital. This is met with commonly in the first born male infant between the third and sixth weeks of life. Progressive and projectile vomiting without bile staining is associated with dehydration and constipation or reduced faecal residue. Peristaltic waves are often observed passing across the abdomen from left to right especially after feeding. A small firm tumour can be palpated in the right upper quadrant or near the midline. No firm diagnosis can be made, however, unless the tumour has been felt. Palpation of the infant's abdomen must be carried out from each side with a hand underneath the bed clothes. If the condition is suspected, a small feed may be given and the abdomen palpated with the left hand standing on the left side of the patient. The tumour is often felt when the pylorus contracts and it may be in the region of the kidney being pushed to the right by the hypertrophied stomach. Whether immediate surgery is indicated as soon as the diagnosis is established, is a matter of opinion. The operation is carried out under local anaesthesia and requires no elaborate preoperative correction of fluid balance as subcutaneous saline solution can be given immediately before operation with hyalase. Rammstead's operation of pyloro-myotomy is done. Practically there is no operative mortality. The alternate method of medical treatment demands several weeks of skilled nursing and involves a very heavy risk of cross infection during the prolonged stay in the hospital. The choice of treatment is thus a matter of balancing the risks.

(B) IN THE FIRST YEAR OF LIFE :

1. *Intussusception :* This is a common form of intestinal obstruction seen in infants between six months and two years of age, and the incidence becomes less as the age increases. In the older age group it is usually associated with a Meckel's diverticulum or submucous lypoma or a polyp which acts as the starting point for the telescoping of the segment of intestine. In a majority of cases, there may not be any apparent cause except hypertrophy of the lymphoid follicle in the Payer's patches. The

history is typical. A male child less than two years old suddenly screams with pain, vomits and becomes pale and limp. This discomfort is intermittent and he continues to have these episodes at intervals of 15 or 20 minutes. In the intervening period the child is quiet and goes to sleep or even feels hungry and is playful. The condition may arise during a mild intestinal upset from a change of diet. In approximately 50% of cases there is no passage of blood per rectum, nor blood is found on the examining finger. The diagnosis depends on the typical history of severe attacks of colic and on careful examination of the abdomen. The emptiness of the right iliac fossa is a reality (Dance's sign). If one feels a distended, gurgling or contracting caecum, the diagnosis of intussusception is virtually ruled out. As with pyloric stenosis, palpation of the mass depends on the patience of the examiner and even in the reasonably early case the sausage shaped mass is felt in the region of the transverse colon. Thus very severe attacks of colic associated with a palpable tumour or the passage of blood and mucus must be taken as urgent indications for surgery. The temperature and pulse rate may not be increased in the early stages and vomiting is unusual and late. A picture of intussusception is, therefore, not that of an ill child passing blood in its stool, but is rather one of a well child who is hungry, sleeping between attacks, has normal temperature and pulse, but is being disturbed by violent spasms of abdominal pain. The passage of one or perhaps two normal stools after the onset of the symptoms adds weight to the diagnosis and recurrent colic of more than four hours duration is an indication for observation in an institution. Rectal examination may reveal blood and mucus on the examining finger and in the late and advanced cases the apex of the intussusception itself. X-ray examinations with barium enema may show the characteristic appearance of "egg in the cup". This is well seen if the barium is allowed to flow while fluroscopic examination is done. Sometimes this manouvre itself will reduce the intussusception. But it is not safe as there may be doubts about the viability of the telescoped segment. Hence laparotomy and reduction and when necessary resection is the treatment of choice.

2. *Inguinal hernia :* This is common in children. Incarceration occurs more commonly than actual strangulation. Treatment differs from that in the older age groups. When the patient is an adult, immediate operation is indicated because of the danger of strangulation. One should try to reduce the hernia carefully by manipulation and after elevating the lower extremity and administration of sedatives parenterally in children. After 24 hours or 48 hours when the oedema around the sac has subsided, operation can be done. In cases where it is not easily reduced, it is safer to do the operation straightaway. Simple herniotomy and closure of the internal ring snugly around the cord will be enough.

3. *Umbilical hernia :* Usually treated conservatively only. But when incarceration occurs and it is difficult to reduce it, immediate surgery is indicated.

(C) CHILD-HOOD LESIONS :

1. *Acute appendicitis :* It is the most common abdominal surgical emergency in children. Even the most experienced observer at times finds the diagnosis difficult. The pathological changes of acute appendicitis

may progress with great rapidity in the child and it is only in the early stages of the disease that the acute obstructive lesion can with any certainty be differentiated from the acute catarrhal type. The distinction depends largely upon the history rather than on the physical signs. It is, however, in this early stage the family physician most needs to be able to make an accurate diagnosis, and to have some idea how long it would be safe to wait before admitting the child in the hospital or in an institution. True appendicitis of the catarrhal or obstructive variety usually progresses with sufficient rapidity for the diagnosis to be very clear-cut and obvious by the time the child reaches the hospital. But there is a dangerous phase when physical signs are almost absent and it is on this point the consultant or the hospital admitting medical officer are apt to ignore the observation of the family doctor who has sent the case for admission.

The triad of abdominal pain, vomiting and fever in a child must be regarded as indication of appendicitis until proved otherwise. Children with acute appendicitis tend to adopt a characteristic attitude. They usually lie on their back with the knees drawn on to the abdomen or curled on their sides. Abdominal breathing may be replaced by thoracic breathing indicating splinting of the abdominal muscles. There is a characteristic fetor oris which seems to be more marked in child hood than in the adult. In the later stages associated with toxemia there may be smell of acetone.

Pain is often difficult to assess, but most children indicate the presence of the pain by their behaviour. A child usually indicates abdominal pain by pointing to the umbilicus. In many young babies the caecum may not have attained its adult site. It may be sub-hepatic, lumbar, pelvic or freely mobile and hence the site of tenderness also varies. The inflamed appendix is tender wherever it is situated and a localised tender area in the abdomen of the young child is of great significance. It may be in the right loin, under the liver, or centrally in the abdomen. It may be just above the pubis, if the appendix is pelvic in position. Muscle guarding is frequently present. Psoas spasm may be present in retrocaecal appendicitis. The pain of acute mesenteric adenitis on the other hand is usually along the right border of the rectus muscle.

The acute obstructive variety of appendicitis is the one which is more apt to proceed to gangrene. In small boys the " cremastric reflex sign " is of great diagnostic value. In the normal child the right testis is briskly elevated as soon as the skin of the lower abdomen is touched. To elicit this physical sign in appendicitis, the doctor's right hand is placed across the right iliac fossa and is held gently in position until the right testis drops back into the scrotum following the initial abdominal response. By gentle but quick flexion of the fingers at the metacarpo-phalangeal joints one can elicit any deep tenderness and if this flick is accompanied by cremasteric contraction and elevation of the right testis, it is a sure sign of true abdominal mischief. If the sign is strongly positive and even if the tongue is clean and there is no fetor oris, but a history suggestive of appendicitis, there should be no hesitation in opening the abdomen. Rectal examination may be extremely misleading in children. So called " high

rectal tenderness" depends entirely on the length of the examiner's finger and the strength of his push. On the other hand, a very careful inspection of the anus with the skin folds separated in a good light may well reveal the presence of active thread worms and that might explain the abdominal symptoms in many cases. The leucocyte count may range from 8000 to 35000 per c. mm.

Differential diagnosis includes many diseases which cause abdominal pain. Acute mesenteric adenitis simulates closely. Acute gastro-enteritis, urinary tract infection, basal pneumonia, exanthematous diseases, primary peritonitis (mostly in girls), acute hepatitis, etc., closely mimic appendicitis. Unless there is consistent evidence of low right sided abdominal tenderness, one should not invoke a diagnosis of acute appendicitis, if there is evidence of acute respiratory diseases. Pyelitis, more common in girls than boys, is frequently accompanied by tenderness along the line of the ureter, but the tongue is clean, there is no fetor oris and the urine may be hazy or cloudy. Inflammation of a pelvic appendix may produce frequency of micturition, dysuria and sometimes even retention of urine. In these cases urine examination shows only scanty pus cells.

In a few cases, especially the retrocaecal and pelvic types may become walled off from the general peritonial cavity by adherent bowel or omentum. The younger the child the more mobile is the omentum and in the baby it is very thin and plays little part in localising; but it is a fallacious tradition that babies do not form inflamatory mass. They do, though not so often as the older children or adults.

Treatment: Acute appendicitis requires appendicectomy. Even in suspected cases of mesenteric adenitis, it is better to open and confirm than leave a truly inflamed appendix behind to proceed to rupture later. In the presence of a mass, constant observation is necessary. If there is a tendency for the mass to increase in size and the temperature persists or raises, incision and drainage of the abscess at the firist stage and later interval appendicectomy (afer three months or so) is done. If there is no increase in size and the temperature and the lump settle down with antibiotic therapy, interval appendicectomy is done. Appendicectomy in childhood causes very low morbidity and almost negligible mortality.

2. *Meckel's diverticulum:* It is a persistence of that portion of the vitelline duct which in embryonic life opens into the ileum. Clinically Meckel's diverticulum resembles acute appendicitis, but the diagnosis is established only at operation. It may manifest itself as an intussusception with itself as the starting point. Sometimes it presents as acute intestinal obstruction due to adhesions between it and the neighbouring intestines. When there is peptic or pancreatic mucus membrane in the diverticulum, it may present itself with haemorrhage or perforation. Treatment is surgical. When appendicitis is suspected and abdomen opened and a normal appendix is found, a search for Meckel's diverticulum should always be made.

3. *Trauma:* Any discussion of acute abdominal emergencies in children must include acute trauma. The large number of automobile accidents and accidents in the play fields and homes claim many children as their victims. Closed injuries cause

rupture of the hollow viscera like the stomach, intestines and bladder. Intra-abdominal haemorrhages occur from a ruptured liver or spleen or pancreas or a torn mesentery. Open or penetrating injuries may produce also perforation or haemorrhage. They always require surgical exploration for confirmation and repair. Associated injuries to the thorax, pelvis and spine should not be overlooked. Diagnosis of acute intra-abdominal injury is based on a history of trauma, abdominal rigidity, tachycardia, shock, shoulder pain and x-ray evidence of free air in the abdominal cavity.

4. *Helminthic infestations :* Round worm infestation of the intestines in children causes colicky pain with vomiting and may simulate intestinal obstruction due to intussusception. History of having passed round worms in the vomit or motion and finding of cysts in the motion will help. It is said very often that the presence of thread worms indicates the presence of round worms in many children. Occasionally the plain x-ray will show the presence of the round worm—especially a barium meal x-ray.

Treatment : When there are signs of obstruction, it is better to open the abdomen, confirm the diagnosis and remove the worms by an enterostomy opening. In other cases worm treatment repeated at intervals of two or three weeks will control the infestation.

CONCLUSION:

Little children often cannot speak. Our responsibility to them is great. We should never dismiss a child if there is the slightest doubt in our minds concerning the pathological state inside the abdomen. We must keep them under our observation. The diagnosis is either confirmed or revised. An abdominal pain which wakes the child at night is a factor in the history which points to a surgical lesion in the abdomen. Six hours of abdominal pain associated with vomiting and unrelieved by an enema is an indication of a surgical lesion. It is better to open the abdomen when in doubt than to leave an obstructive appendix inside to burst later like a 'time bomb'. Timely intervention reduces the incidence of perforation and also mortality.

AMUSING MINUTES

The doctor knocked at the bed room door, before entering to visit his patient, a young woman. Going to the bed, the doctor pulled back the covers and ordered, "Take off your night gown".

"Altogether ?", asked the patient.

"Of course," answered the doctor.

When it was done the doctor gave her a thorough examination, top to bottom, fore and after. When he had finished, the lady said, "Doctor, I'm curious about something. May I ask one question ?"

"Certainly".

"Doctor, why did you knock ?"

—*Unichem Medical Notes.*

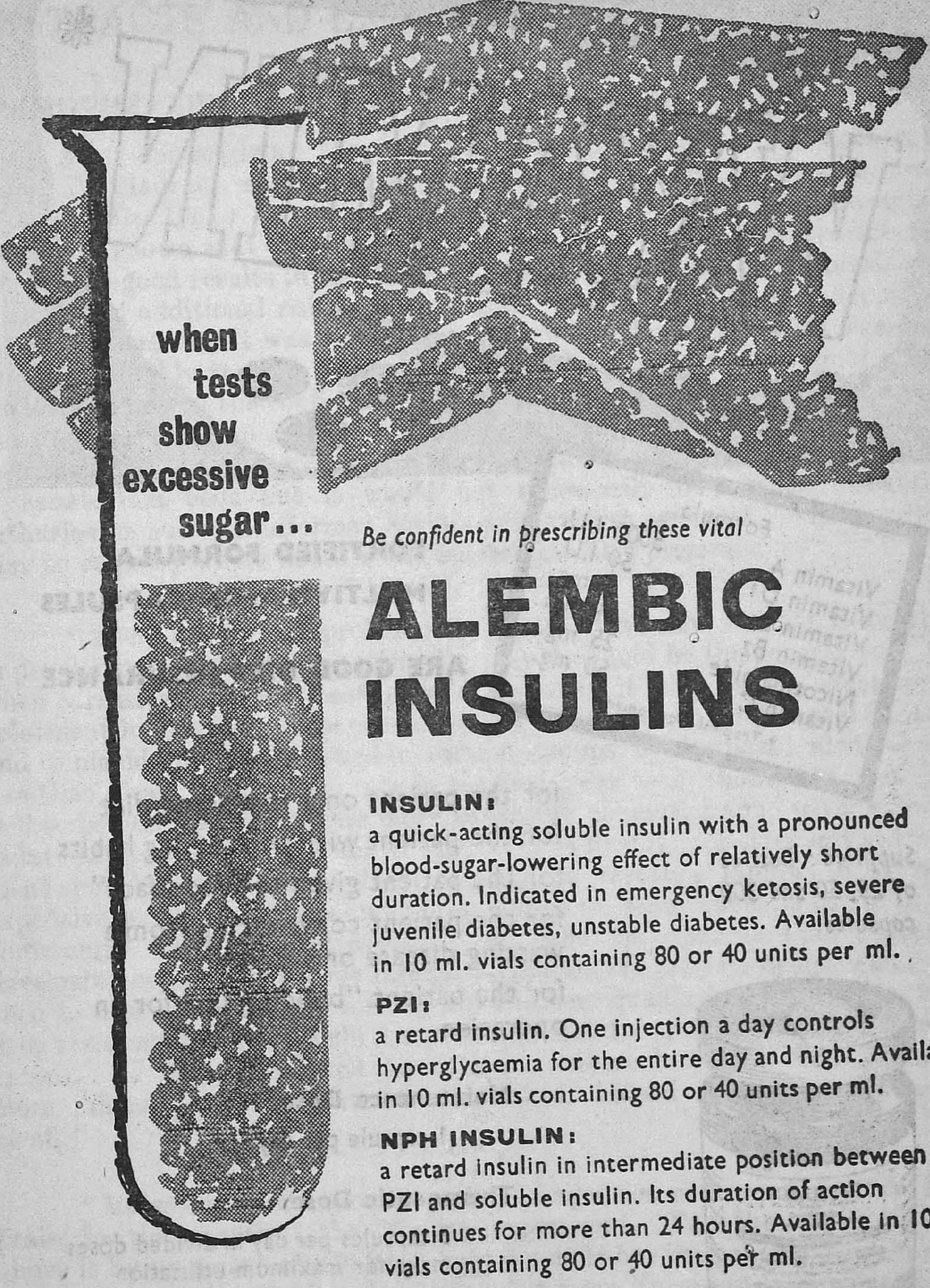

when tests show excessive sugar...

Be confident in prescribing these vital

ALEMBIC INSULINS

INSULIN:
a quick-acting soluble insulin with a pronounced blood-sugar-lowering effect of relatively short duration. Indicated in emergency ketosis, severe juvenile diabetes, unstable diabetes. Available in 10 ml. vials containing 80 or 40 units per ml.

PZI:
a retard insulin. One injection a day controls hyperglycaemia for the entire day and night. Available in 10 ml. vials containing 80 or 40 units per ml.

NPH INSULIN:
a retard insulin in intermediate position between PZI and soluble insulin. Its duration of action continues for more than 24 hours. Available in 10 ml. vials containing 80 or 40 units per ml.

When the patient is on a diet, specify AMUROL— a combination of two artificial, non-caloric sweetening agents in a readily soluble tablet form.

You can put your Confidence in *Alembic*

A-61-517 EVEREST

WYAMIN*



Formula

Vitamin A	5000 I.U.
Vitamin D†	50 I.U.
Vitamin B1	5 mg.
Vitamin B2	4 mg.
Nicotinamide	25 mg.
Vitamin C	50 mg.

† Tropical requirements

FORTIFIED FORMULA MULTIVITAMIN CAPSULES

ARE GOOD DIET INSURANCE

- for the patient on a restricted diet
- for the patient with poor eating habits
- for the patient given to "food fads"
- for the patient convalescing from a wasting disease or surgery
- for the patient "building up" for an operation

Supplied: Bottles of 25, 50 and 300 capsules.

Maintenance Dose

1 capsule per day

Therapeutic Dose

3 capsules per day in divided doses make for maximum utilisation

a century of service to medicine Wyeth *1860-1960*

JOHN WYETH & BROTHER LIMITED, LONDON

(Incorporated in England with Limited Liability)

Indian Branch: Steelcrete House, Dinshaw Wacha Road, Bombay I.

*Trade Mark

ABSTRACTS AND EXCERPTS

CHEMOTHERAPY OF TUBERCULOSIS IN INDIA:

After summarizing the findings of the Tuberculosis Chemotherapy Centre in Madras, an Editorial article in the British Medical Journal (October 21, 1961) concludes — "These results are very encouraging. They have shown that even under the poorest social conditions chemotherapy can give as good results in the home as in a sanatorium or hospital, and without any additional risk to the contacts. But the conditions under which out-patient treatment was carried out were not typical: the work was done by a large, highly trained, well equipped, and devoted team who could afford the time to obtain the confidence of their patients and their patients' families and to supervise them closely. It would certainly be cheaper to provide such teams in developing countries than to provide and staff large numbers of sanatorium beds but it would not necessarily be easier. Devoted, enthusiastic, and well-informed leaders are the first essential. These are not easy to come by where doctors and leaders are at a premium.

"There are further problems to solve, but we now at least know that in developing countries out-patient treatment should be the general rule, for when carried out in the best possible manner it can be as effective as treatment in hospital. The chemotherapy used in these trials—oral P. A. S. and isoniazid initially, followed in certain groups by isoniazid alone — was less than ideal. The failure rate in the first year was about 10%. It has still to be determined whether more extensive chemotherapy, with a lower failure rate or none, might not in the end save money. Better initial treatment should greatly reduce the necessity of treating failures with very expensive second-line drugs and the spread of resistant tubercle bacilli in the community. This is controversial; but what is clear is that in many developing countries valuable foreign currencies are used on drugs which are then so mishandled by uninformed practitioners qualified or unqualified, that drug resistant tubercle bacilli are produced and disseminated to an alarming extent. If this is allowed to continue tuberculosis will become much more difficult and expensive to control, if indeed it can be controlled at all."

"Meantime all the governments and agencies concerned deserve high praise for the success of the Madras experiment. For the work outlined above is by no means all that has been done. It has been shown, for instance, that Indian strains of tubercle bacilli differ from European in pathogenicity. The prevalence and significance of primary drug-resistance has been investigated. Much work has been done on the problem of self-medication at home. And to all this research the highest scientific standards have been applied. But perhaps the most remarkable achievement of the Madras team is to have followed up all patients now for more than three years."

— *B. M. J., October 21, 1961 (Editorial)*

EVALUATION OF THE STEROID TREATMENT OF ASTHMA SINCE 1959:

(H. S. Baldwin, M. Dworetzky, and N. J. Isaacs – Journal of Allergy (J. Allergy) 32, 109 – 118, March – April, 1961. 12 refs)

The authors report from New York Hospital—Cornell Medical Center, New York, that during the past 10 years 48 patients with severe bronchial asthma have been treated continuously for one to 9 years (average period 4·4 years) with various corticosteroids, while 39 other asthmatic patients were given similar but intermittant treatment.

The majority of the patients (69) received prednisone in an average maintenance dose of 10 mg., while the maintenance dose of triamcinolone was 7 mg. and that of dexamethasone 0·9 mg. There was only one death from asthma, this occurring in a woman aged 52 from whom the steroid was withdrawn while she was away from the author's supervision. In only 8 of the 87 cases did the corticoids fail to bring symptomatic relief. There were no serious metabolic side-effects, a fact which is attributed to the minimum maintenance doses used. When an operation proved necessary, supplementary doses of corticoid were given and no instance of adrenal shock occurred in these cases.

— Abstracts of World Medicine - Vol. 30, No. 3 - para 621 - page 199

*   *   *   *

RECURRENT URINARY INFECTION IN GIRLS:

(D. I. Williams and D. E. Sturdy, Archives of Disease in Childhood (Arch. Dis. Childh) 36, 130 - 136, April, 1961. 9 figs., 5 refs)

In this paper from the Hospital for Sick Children, Great Ormond Street, London, a study is reported of children, almost always girls, who have recurrent urinary infections without gross deformity of urinary tract. The authors state that it used to be their practice to give continuous chemotherapy in such cases, but follow-up investigation revealed that in a significant proportion chronic pyelonephritis developed later in life, as demonstrated by pyelography. The significant features of the pyelogram in chronic pyelonephritis are described and illustrated and 4 cases are briefly reported.

Over a recent 2 year period mild obstruction of the bladder neck was diagnosed in 28 patients, 24 of whom were operated on. The authors note that the condition in the female differs from that in the male in that progression to retention and hydronephrosis is uncommon, but it predisposes to infection and pyelonephritis. In diagnosis, true residual urine is of great significance, as is definite trabeculation of the bladder. A cystogrm during micturition will reveal ureteric reflux. A Y - V plasty of the bladder neck by open operation resulted in improvement in 12 out of 14 patients followed up for at least 6 months, the urine continuing to be sterile. The remaining 2 patients had severe reflux. In general. incontinence improved or was cured.

Mention is made of the megacystis syndrome - that is, a large non-trabeculated thin-walled bladder associated with a lax ureteric-orifice and bilateral reflux. In the past such cases have been treated conservatively, but recently the authors have carried out operations to prevent reflux, as advocated by Paguin, "the comparative results of which are not yet available".

— *Abstracts of World Medicine - Vol. 30, No. 3, page 250, para 787*

* * * *

WHY APPLY A POSTOPERATIVE DRESSING?

As a result of experience with experimental operations on dogs, Haeger and Liedberg of Malmo, Sweden (Nord. Medicin, 66 : 960, 1961) decided to try leaving off the postoperative dressing altogether in a series of 163 patients operated on for abdominal or thoracic conditions, while leaving a control series of 60 with conventional dressings. They found that the rate for wound complications was lower (6·1%) in the uncovered series than in the dressed series (30%). The rate for pulmonary complications was about the same in both series.

— *World Medical Journal - September 1961*

OBITUARY.

We deeply regret to record the death of Dr. Sripathi Rau, M.B.,B.S., a member of the Madras City Branch of the I. M. A. He passed out of the Madras Medical College in the year 1947 and was engaged in a lucrative practice along with his father Dr. U. L. Narayana Rau. He went abroad in 1949 and was away for an year and half at U. S. A. and England to specialise in Paediatrics. He was a member of the executive committee of the Madras City Branch and a member of the Council of the Madras State Branch of I. M. A. He was the joint secretary of the Madras City Branch and took keen interest and active part in the Silver Jubilee Celebrations of the Madras City Branch. His untimely death at the age of 40 is a sad loss to the Association. We offer our heart-felt sympathy to his aged father and his family.

ASSOCIATION NOTES

BRANCH NOTES

Coimbatore Branch:

1. The monthly meeting of the Coimbatore District Medical Association was held on Saturday the 16th September, 1961 at 6 P. M. in the premises of the Association. 70 members were present. Dr. G. T. Gopalakrishna Naidu, L. M. P., L. P. H., the President presided.

The President introduced, in a short speech the speaker of the day, Dr. K. S. Subramaniam, B. SC., M. B., B. S., D. O., F. R. C. S., Assistant Professor of Ophthalmology and Head of the Department, Medical College, Calicut, and requested the speaker to deliver his address. Dr. K. S. Subramaniam addressed the gathering on "Some Neuro-Ophthalmological Problems" which was very much appreciated by the members.

After the usual questions and answers, there was a film show on "Epidural Anaesthesia" and "Conservative Treatment of Intervertebral Disc Lesion" by the kind courtesy of Messrs Suhrid Geigy Ltd., Bombay.

2. The monthly meeting of the Coimbatore District Medical Association was held on Saturday, the 30th December 1961 at 6 P. M. in the premises of the Association. 60 members were present. Dr. G. T. Gopalakrishna Naidu, L. M. P., L. P. H., the President presided.

The President introduced the speaker of the day, Dr. G. Venkataswamy, B. A., M. B., B. S., D. O., Professor of Ophthalmology, Medical College, Madurai, and requested him to address the gathering. Dr. G. Venkataswamy then addressed the meeting on "Eye Examination in General Diseases". With the aid of very interesting and instructive colour slides the speaker spoke of the "Common Eye Conditions" in daily practice. The interesting and erudite lecture and some of the very fine slides projected by him were very much appreciated by the members.

Madras City Branch:

1. An ordinary committee meeting of the association was held on 12th December, 1961, Dr. R. G. Krishnan presiding.

Dr. V. Samuel moved that the State branch be requested to contribute Rs. 10,000, towards the building fund of the Madras branch, to accommodate the offices of the Madras State Branch at the building. Dr. K. V. Swamy seconded the resolution.

A condolence resolution was moved from the chair to mark the death of Dr. K. S. Jaganathan, Pathologist, Madras. Three minutes silence was observed.

2. A special executive committee meeting was held on 28—12—1961.

The draft annual report for the year 1960—'61 as presented by the secretary was adopted.

Madurai Branch:

A monthly meeting of the Madura Medical Association was held on Saturday, the 16th December, 1961, under the Presidentship of Dr. Abdul Sattar, L. O., Madurai.

Dr. K. A. Kalyanam, F R. C. S. (E), D. M. R., Honorary Clinical Professor of Surgery, Madurai Medical College, and Honorary Surgeon, Government Erskine Hospital, Madurai, gave an interesting lecture on "The Importance of Scout X-Ray Films in the Diagnosis of Abdominal Pathology" with slide demonstration of representative skiagrams.

Nagapattinam Branch:

A clinical meeting was held on 3rd December, 1961 at the Government Hospital, Nagapattinam, Dr. A. T. Thiagarajan presiding.

Dr. N. Srinivasan, B. SC., M. B., B. S., gave an interesting lecture on "The Recent Views about the Peptic Ulcers and Their Treatments".

Nilgiris Branch:

The monthly meeting of the Nilgiri District Branch of the Indian Medical Association was held on 13th January, 1962 in Military Hospital, Wellington. Dr. H. C. Berlie, one of the senior members of the Association presided.

Dr. C. N. Santhanam, M. S., Coimbatore gave an interesting talk on "Pain in the Right Iliac Fossa".

Dr. P. K. Kalyanaraman and Major N. R. Krishnan also spoke dealing with short case histories.

Salem Branch:

A monthly meeting of the Salem branch of the I. M. A. was held on 19th November 1961, Dr. R. N. Sujir, M. B., B. S., presiding. Dr. V. Hariharan, M. B., B. S., M. P. H. (Harvard), Assistant Director of Public Health, addressed the members on "The Role of B. C. G. in the Control of Tuberculosis".

Tiruchy Branch:

Annual Meeting.

1. The 32nd Annual Meeting of the Association was held on Sunday, the 29th October 1961 in the Association premises. 80 members and 20 guests were present. After prayer by Kumari R. Lalitha, the President Dr. P. V. Sundaram welcomed the members and guests. Dr. N. V. Muthukrishnan, the Honorary Secretary, read the annual report for the year 1960—'61 and it was unanimously adopted. The statement of accounts for the year was also read.

Then the following members were unanimously elected as office-bearers:

President	:	Dr. T. V. Ranganathan
Vice-President	:	Dr. C. Ramanujachary
Honorary Secretary: (Re-elected)	:	Dr. N. V. Muthukrishnan
Joint Secretary & Treasurer: (Re-elected)	:	Dr. M. V. A. Iswaran

The newly elected President, Dr. T. V. Ranganathan took the chair. The President expressed his thanks for electing him as the President for the year and introduced the lecturer, Dr. M. D. Ananthachary, M. D., to the members and requested him to give his talk on "Blood Pressure-Its Significance-Some Observations". Then Dr. Jayakumar, M. D., and Dr. C. N. Santhanam, M S., delivered lectures on "Newer Trends in Medicine" and "Acute Abdominal Emergencies in Infants and Children" respectively. All the lectures were very much appreciated by the members.

Inaugural Meeting.

2. The 33rd Inaugural Meeting of the Association was held on Saturday, the 9th December 1961 in the Association premises, Tiruchy. Dr. T. V. Ranganathan, the President presided.

The President introduced the lecturer of the day, Dr. Vishnu Sarma, M. A., M. D., B. Chir, M. R. C. S., L. R. C. P., D. G. O., Fellow of the Royal Society of Medicine, London, Assistant Professor of Obstetrics and Gynaecology, Stanley Medical College, Madras to the members and requested him to give his talk on "Abdominal Tumours in Gynaecological and Obstetrical Practice". After the lecture, there was a discussion in which many members took part.

INDIAN COUNCIL OF MEDICAL RESEARCH

(COLONEL AMIR CHAND TRUST FUND PRIZES FOR MEDICAL RESEARCH)

Lieut.-Col. Amir Chand, lately Principal of Lady Hardinge Medical College, New Delhi, donated Rs. 50,000/- to the Indian Council of Medical Research for creating a prize fund. From the interest earned by this sum, prizes are awarded for the best published research work in medical sciences. The governing body of the Council has constituted a trust called the "Colonel Amir Chand Trust" for the administration and management of the fund.

The prizes are awarded annually on an all-India basis for the best published research work in any subject in the field of medical sciences including clinical research. The term 'Clinical Research' covers research into the mechanism and causation of disease and its prevention and cure, and includes work on patients in hospitals, field studies in epidemiology and social medicine and observations in general practice.

It has been decided to award four prizes in 1962 each of Rs. 300/- to Indian nationals of not more than 40 years of age on 1st January, 1962, for the best research papers in medical sciences published by them during 1961 in Indian or foreign journals as a result of work done in any institution in India. These prizes will be known as 'Shakuntala Amir Chand Prizes'.

Those eligible for the prizes are *medical or non-medical graduates.*

Selections for the award of the prizes will be made by a selection board.

In the case of a joint authorship of a publication, the prize shall be divided between the authors in such proportion as the selection board may decide. The role of the person who applies for the prize should be clearly indicated so as to make it easy to determine whether the major part of the work has been done by that person.

The award of the prizes will be announced at the meeting of the Council's advisory committees in November/December, 1962.

Candidates for award of prizes are required to submit *ten reprints* of their papers published during 1961. These should be sent to the DIRECTOR, INDIAN COUNCIL OF MEDICAL RESEARCH, P. O. BOX 494, NEW DELHI, so as to reach him *not later than 1st September, 1962.* The papers should be accompanied by a short biographical sketch and two copies of passport size photographs of the candidate/candidates concerned.

Prescribed by Doctors
in 108 Countries all over the World

HADENSA for PILES
HAEMORRHOIDS, FISSURES and BLEEDING

HADENSA, recommended by Doctors in 108 countries, gives prompt and lasting relief from Piles, Haemorrhoids and Fissures; relieves pain and itching and is an excellent lubricant.

HADENSA contains no narcotics which may mask serious rectal pathology—It is non-staining.

FORMULA :

Monochlorcarvacrol	... 0·01 g.	Ichtham I. P.	... 0·20 g.
Menthol I. P.	... 2·50 g.	Oleum Arachis I. P. ...	18·00 g.

Adeps Lanae Base to 100·00 g.

Only genuine with this mark

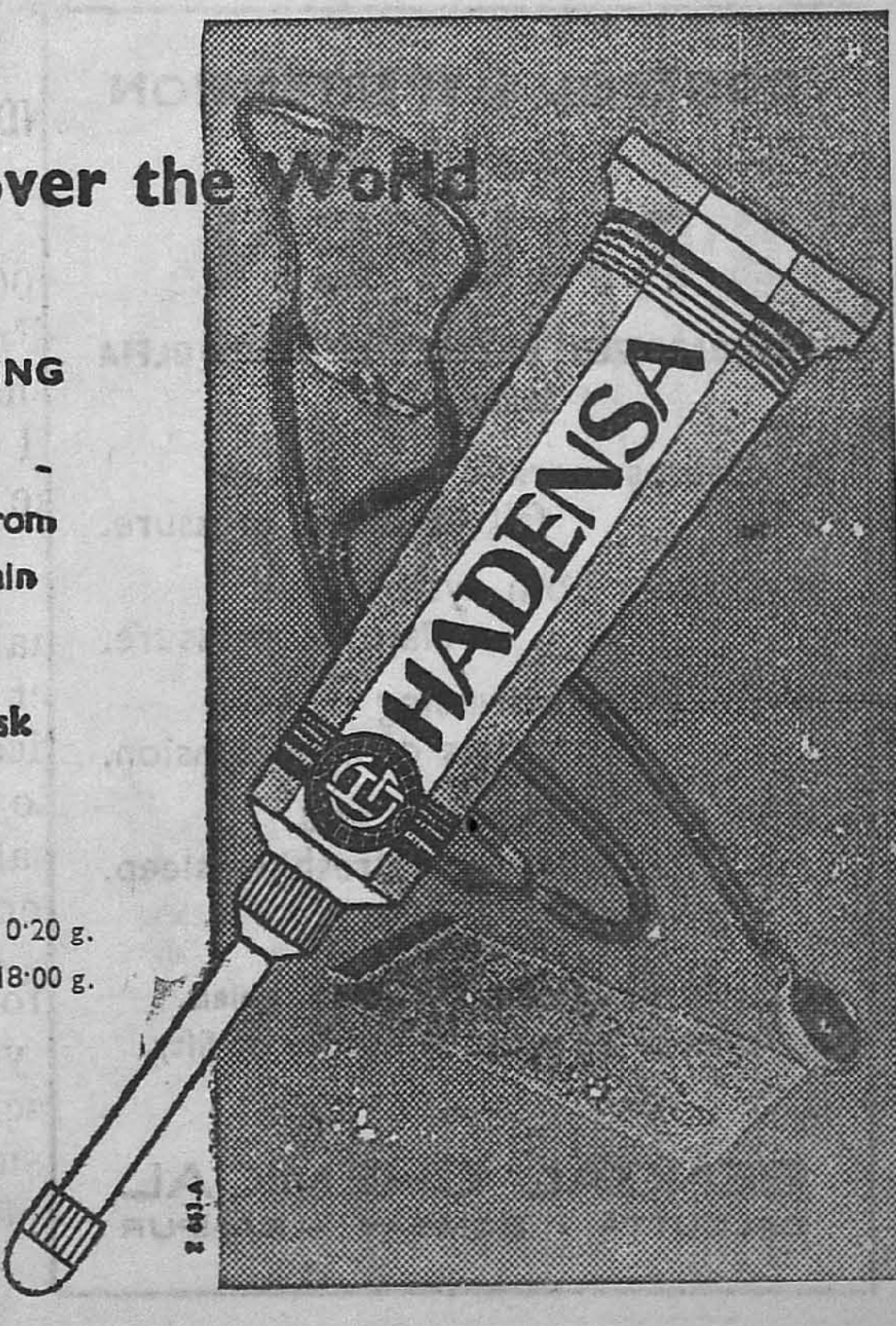

THE WORLD RENOWNED GERMAN PILE REMEDY
NOW MANUFACTURED IN INDIA

CONTROL HYPERTENSION

Successfully with

RALFEN

STANDARDIZED EXTRACT OF RAUWOLFIA SERPENTINA

- Causes marked but gradual fall in blood pressure.
- Lowers both systolic and diastolic pressure.
- Relieves distressing nervous symptoms of hypertension.
- Is a mild hypnotic and produces refreshing sleep.

Supplies :

Liquid Extract : In 28 ml. phials.
Tablet of 1·6 mg. : In bottles of fifty.

★

BENGAL CHEMICAL
CALCUTTA · BOMBAY · KANPUR

TO LET

UNI-ENZYME

TABLETS

for

FLATULENCE

AND

DYSPEPSIA

- ANTI-SPASMODIC
- ANTI-ALLERGIC
- ANTI-INFECTIVE
- DIGESTIVE

effectively helps to overcome abdominal pain and discomfort due to its antispasmodic action on the alimentary canal & adsorbent action.

Each tablet contains :

Fungal Diastase	125 mg.
Pancreatin (Enteric-coated)	100 mg.
Pepsin	15 mg.
B_1	2 mg.
B_2	2 mg.
Nicotinamide	25 mg.
Iodochlorohydroxy-quinoline	125 mg.
Diphenhydramine Hcl.	20 mg.
Homatropine Methyl Bromide	1.25 mg.
Activated Charcoal	125 mg.

UNICHEM LABORATORIES
BOMBAY 26.